

Acute Toxicity Evaluation of a Crude Sap Isolated from *Nypa fruticans* Wurmb. in Sprague Dawley Rats

(Penilaian Ketoksikan Akut Air Nira yang dipencilkan daripada *Nypa fruticans* Wurmb. pada Tikus Sprague Dawley)

SITI FATIMAH ROQIAH YAHAYA*, NIZA SAMSUDDIN, SUHANA MAMAT, ROZITA HOD, NOR ZAMZILA ABDULLAH & NOR AZLINA A RAHMAN

ABSTRACT

Nypa fruticans Wurmb. (*nipa palm*) sap, locally known as air nira or tuak, is a sweet natural beverage in Malaysia with antioxidant potency beneficial for human health. However, nypa sap lacks scientific attention with no toxicity study has been established. Therefore, this study was performed to evaluate the acute toxicity of nypa sap in the female Sprague Dawley rats. Twenty-five female rats were randomly divided into one control group and four treated groups. Treated groups were orally administered with doses of 5, 50, 300, and 2000 mg/kg of nypa sap, while the control group had received normal saline solution. The animals' vital signs and mortality were recorded daily at an interval of 30 min and continued up to 14 days. Their blood samples and organs were harvested for toxicity analysis to assess liver and kidney function, lipid profile, and full blood count. The acute toxicity test via measurement of the biochemical and haematological parameters had shown that there was no significant difference between the treated and control groups. However, the blood glucose level in the treated groups (at higher doses of 300 and 2000 mg/kg, respectively) was significantly decreased. A similar trend was recorded for mean corpuscular volume (MCV) albeit in the treated group of 50 mg/kg doses. Histopathological examination of the organs showed no signs of abnormality in both treated and untreated groups. Overall, the results showed that consumption of nypa sap is potentially safe with no acute toxic effect on the laboratory rat models.

Keywords: Acute toxicity; biochemical parameters; haematological parameters; histopathology; *Nypa fruticans* Wurmb. sap

ABSTRAK

Cairan tumbuhan daripada pokok *Nypa fruticans* Wurmb. (*nipah*) atau dikenali sebagai air nira atau tuak adalah minuman semula jadi yang manis di Malaysia dengan potensi antioksidan yang memberi manfaat untuk kesihatan manusia. Walau bagaimanapun, air nira ini kurang mendapat perhatian saintifik dengan kajian ketoksikan masih belum diterbitkan. Oleh itu, kajian ini dilakukan untuk menilai ketoksikan akut air nira terhadap tikus Sprague Dawley betina. Dua puluh lima ekor tikus dibahagikan secara rawak kepada satu kumpulan kawalan dan empat kumpulan rawatan. Kumpulan rawatan diberikan air nira secara oral pada dos 5, 50, 300 dan 2000 mg/kg, sementara kumpulan kawalan diberikan larutan garam. Tanda-tanda vital dan kematian haiwan dicatat setiap hari dalam selang masa 30 minit dan berterusan selama 14 hari. Sampel darah dan organ semua tikus diambil untuk analisis ketoksikan untuk menilai ujian fungsi hati dan ginjal, profil lipid serta ujian bilangan sel darah. Ujian ketoksikan akut melalui pengukuran parameter biokimia dan hematologi telah membuktikan bahawa tiada perbezaan yang ketara antara kumpulan rawatan dan kumpulan kawalan. Walau bagaimanapun, tahap glukosa darah dalam kumpulan rawatan (pada dos yang tertinggi 300 dan 2000 mg/kg) berkurangan secara ketara. Keputusan yang sama telah direkodkan untuk purata isi padu min korpuskular (MCV) apabila dirawat pada dos 50 mg/kg. Pemeriksaan histopatologi organ tidak menunjukkan tanda keabnormalan dalam kedua-dua kumpulan rawatan dan kawalan. Keseluruhannya, keputusan menunjukkan bahawa pengambilan air nira adalah berpotensi selamat tanpa mempunyai kesan toksik akut ke atas model tikus makmal.

Kata kunci: Air nira (*Nypa fruticans* Wurmb.); histopatologi; ketoksikan akut; parameter biokimia; parameter hematologi

INTRODUCTION

Nypa fruticans Wurmb., popularly known as the nipa palm, is a species that thrives in the river estuaries and is native to the coastline all over Malaysia. The nipa palm contains flower cluster (inflorescence) that can be tapped to yield a beverage known as *N. fruticans* Wurmb. sap, palm juice, *tuak* or *nira* as it is known locally (Minh 2014; Osabor et al. 2008; Prasad et al. 2013). *N. fruticans* Wurmb. sap is traditionally consumed by rural communities in Malaysia as a refreshing natural beverage. People in many Asian countries of tropical climate use *N. fruticans* Wurmb. sap to make palm wine, vinegar, and a type of sweetener called *nisan*, which is a concentrated nypa sap produced by heating (Ho et al. 2007; Hossain & Islam 2015; Minh 2014; Nur Aimi et al. 2013; Nguyen et al. 2016; Osabor et al. 2008). Numerous studies reported that different parts of the *N. fruticans* Wurmb. such as leaves, stems, fruits, and roots have been used generally in the treatment of diseases such as asthma, leprosy, tuberculosis, sore throat, and liver disease. In addition, the whole plant parts were also used as a traditional treatment to snake bites, as a sedative, pain reliever, and carminative (Bandaranayake 1998; Prasad et al. 2013; Rahmatullah et al. 2010). Moreover, the aqueous extract of *N. fruticans* Wurmb. vinegar exerts its anti-diabetic and anti-hyperglycaemic activities through insulin stimulatory (Beh et al. 2017; Yusoff et al. 2017, 2015a, 2015b). Furthermore, the Malaysians believed in the potential of *N. fruticans* Wurmb. sap in treating fever, diabetes, high blood pressure, gout, and kidney stone (Mohd et al. 2011).

A recent study by Phetrit et al. (2019) found that the total phenolic and flavonoid compounds of nypa sap were 249.35 and 48.90 mg/100 g, respectively. Three predominant phenolic compounds in nypa sap were vanillic acid, rutin, and trans-ferullic acid with the reported concentration of 29.31, 11.23, and 7.02 mg/100 g, respectively (Phetrit et al. 2019).

Even though *N. fruticans* Wurmb. sap is being used extensively by the locals for health benefits in treating various ailments, little is known about its toxicity effects, especially towards the liver and kidneys. Recent studies have reported that nypa sap and palm sugar do not exhibit any toxicity to the brine shrimp (*Artemia salina*) (Hafizi et al. 2018; Sabri et al. 2018). Another study also reported that the extracts of *N. fruticans* Wurmb. leaves and stem did not show toxicity when tested on a rat model (Reza et al. 2011). To date, no study has evaluated *N. fruticans* Wurmb. sap toxicity following the OECD guidelines using the rat model. Hence, this study can provide preliminary toxicology data in Malaysia as a reference for studying the medicinal properties of nypa sap in the future.

Therefore, this study aimed to evaluate the acute toxicity of *N. fruticans* Wurmb. sap on animal models, especially the rat model through biochemical and haematological analyses as well as the histopathological assessment of targeted organs.

MATERIALS AND METHODS

CHEMICALS

All chemicals used in the study were acquired from Scienfield Expertise PLT, Selangor, Malaysia.

ETHICAL APPROVAL

Animal ethics approval was received from the Integrated Centre for Research Animal Care & Use (IACUC) ethical committee, International Islamic University Malaysia (IIUM).

SAMPLE COLLECTION

Fresh samples of *N. fruticans* Wurmb. sap was collected from Kampung Pulau Gajah, Kelantan, Malaysia. Several parts of *N. fruticans* Wurmb. were authenticated by Dr Shamsul Khamis, a botanist from Herbarium UKMB, Faculty of Science and Technology, Universiti Kebangsaan Malaysia (UKM). The sample was labelled with the voucher specimen's number of PIUM 0314. The long stalk containing inflorescence was cut and tapped slowly to produce nypa sap. Next, a sterile plastic bag was tied at the end of the stalk and left for 5-6 h to collect the sap. The collected sap was immediately transferred into 500 mL Schott bottles and kept on ice. The samples were taken to the laboratory and stored at -80 °C prior to analysis.

SAMPLE PREPARATION

In brief, 500 mL of the frozen samples were freeze-dried for 1 week using a freeze-dryer (Christ, Beta 2-8 LDplus). The freeze-dried samples were then stored at 4 °C until further analysis.

EXPERIMENTAL ANIMAL

The experimental procedure and handling of the animals were conducted according to the guidelines 420 and 423 of OECD (OECD 2001a, 2001b). Female Sprague Dawley rats with body weight ranged between 184 and 260 g were purchased from the Comparative Medicine and Technology Unit (COMeT), Universiti Putra Malaysia (UPM), Serdang, Malaysia. They were maintained under 12 h light-dark cycle with controlled temperature and access to both water and food. All animals were randomly

divided into experimental and control groups and housed in separate steel cages. The rats were acclimatised for 7 days as an adaptation to the laboratory environment (temperature of 27 ± 2 °C, relative humidity) prior to the experiment.

ACUTE TOXICITY STUDY

A total of 25 female rats were divided into 5 groups with 5 rats per group. The rats were weighed and the dose was calculated according to their body weight. Before the treatment, the rats were fasted overnight. The test groups received a single dose of nypa sap at doses of 5, 50, 300, and 2000 mg/kg, respectively, while the control group received normal saline by oral gavage. The dosing volumes of 2 mL/kg were injected to the rats. Treated rats were observed keenly for their mortality, behavioural changes, and signs of toxicity every 30 min for 24 h and for a total of 14 days. Clinical observations included evaluation of the skin, hair, fur, eyes, salivation, motor activity, diarrhoea, sleep, and respiratory patterns, together with the reflexes. Individual body weight was measured before, at several intervals during the 14 days' period of experimentation, and at the end of the experiment. Food consumption was recorded daily throughout the study period. On day 15, all animals were anaesthetised with pentobarbital sodium (50 mg/kg, i.p) (Da Silva et al. 2016). The rats were sacrificed immediately after blood collection by cardiac puncture, and the organs (i.e. kidney and liver) were harvested for histopathological examinations.

HAEMATOLOGY AND BIOCHEMISTRY ANALYSES

After overnight fasting but with access to water, blood samples were collected by cardiac puncture. The blood samples were sent to Gribbles Pathology laboratory for further analyses. The samples were run by using automated model COBAS c 111 biochemistry and COBAS m 511 haematology analysers.

The haematological analysis included red blood cells count (RBC), total white blood count (WBC), haemoglobins concentration (HB), platelets count (PLT), red cell distribution width (RDW) and mean for corpuscular volume (MCV), corpuscular haemoglobin (MCH) including corpuscular haemoglobin concentration (MCHC). Meanwhile, serum samples were examined for blood biochemistry, which includes kidney, liver function tests and lipid profile.

HISTOPATHOLOGY EXAMINATION

The organs (i.e. liver and kidneys) were preserved in 10% (v/v) buffered formalin. Several portions of the organs were sliced, and the tissues were placed in cassettes.

The tissues were embedded in melted paraffin wax, and microtomy was performed to obtain a thin slice of tissue. The tissues were put on microscope slides and stained with haematoxylin and eosin before the microscopic examination was performed. All the histological slides were evaluated by Dr Asmah Hanim, Anatomic Pathologist from the Department of Pathology and Laboratory Medicine, IIUM.

STATISTICAL ANALYSIS

The data collected from biochemical and haematological analyses were expressed as mean \pm SD. One-way ANOVA was used to compare the statistical differences across all groups, and the significant difference between individual groups was determined by post-hoc test. The differences between the comparison groups were considered statistically significant when the *p*-value is less than 0.05.

RESULTS AND DISCUSSION

Medicinal plants are alternative medicines that have been used to treat various diseases due to their advantages such as cost-effective, high accessibility and acceptability, safe and functionally effective (Bakoma et al. 2013). The consumption of medicinal plants by the public is increasing due to the strong belief that these natural products are safe and effective in treating ailments (Bakoma et al. 2013). However, the study on pharmacological and toxicological properties of medicinal plants is still necessary to elucidate the effectiveness and evaluate the risk of their consumption.

Nypa sap is extensively used as an alternative medicine to treat fever, diabetes, high blood pressure, gout, and kidney stone (Mohd et al. 2011). Nevertheless, there are no experimental data on the safety of *N. fruticans* Wurmb. sap. Hence, the toxicological evaluation was performed using the rat model to evaluate the safety of this widely used medicinal plant.

A previous study reported that different parts of *N. fruticans* Wurmb. have great potential as antioxidants. The major phenolic compounds found in the extract of *N. fruticans* Wurmb. fruits were chlorogenic acid, protocatechuic acid, and kaempferol (Prasad et al. 2013). Similarly, a study found that the matured leaf exhibited the highest phenolic compound content followed by the young leaf and fruit-husk of *N. fruticans* Wurmb. (Aziz & Jack 2015). The results of this research supported the previous findings that *N. fruticans* Wurmb. fruits and leaves are the natural sources of antioxidants which might play a role as a defensive agent against free radicals stimulated by the antioxidant properties of polyphenols. In addition, other active compounds in *N. fruticans* Wurmb. might also contribute to its antimicrobial activity. Another study had

demonstrated that *N. fruticans* Wurm. leaves inhibited the growth of common microorganisms such as *Escherichia coli*, *Staphylococcus aureus*, and *Klebsiella pneumonia* (Ebana et al. 2015).

BODY WEIGHT, VITAL SIGNS, AND MORTALITY

All rats were found to be in a healthy condition with no mortality observed throughout the experiment. Body weight of the rats before and after treatment with nypa sap showed a positive growth throughout the study period

(Figure 1). No signs of toxicity were recorded in the rats throughout the study. After the administration of nypa sap, tremor or traumatic state was not being observed in the rats from all experimental groups. In addition, the rats did not exhibit any signs of toxicity such as ruffled fur, salivation, diarrhoea, lethargy, sleep, or coma. Gross examination of the liver and kidneys showed that there was no significant difference between the organs of control and treated groups. Liver and kidneys of treated groups were remained in normal size and showed dark red with smooth surfaces.

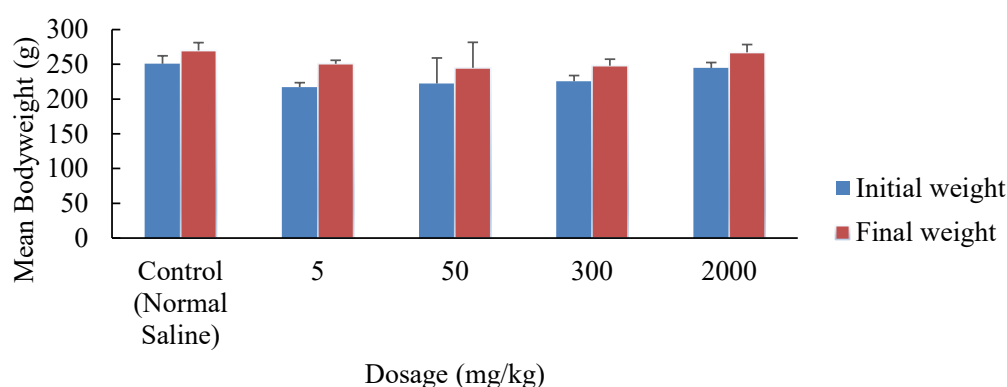


FIGURE 1. The clear trend of increased mean body weight of female rats before and after administration of nypa sap ($n=5$, data express as mean \pm SD)

HAEMATOLOGY EXAMINATIONS

The findings of the haematology test on female rats are presented in Table 1. In this study, several assessments were done to evaluate the toxicity of nypa sap on the rat model. These include the haematological assessment which is relevant since the changes in the haematological system could reflect higher predictive value for animal toxicity (Tamizhazhagan & Pugazhendy 2015).

In our study, MCV in the treated group was significantly decreased as compared to the control group after the rats were given 50 mg/kg of nypa sap. It is plausible that the value of MCV decreased due to the presence of microcytic anaemia in rats; which can be caused by poor dietary intake of iron in the body system (Lu & Wu 2004). This result may be explained by the fact that the value of MCV was high at birth and then

rapidly decreased after weaning but was later remained unchanged for physiological maturity of the rats (Kojima et al. 1999). Moreover, changes in the haematological parameters alone do not indicate the toxic effect towards rats, unless alteration in the histology of bone marrow or spleen is also observed (Ramsingh 2010). Even though the difference was significant, the value of MCV was still within the normal range for laboratory rats (Giknis & Clifford 2006), probably due to the physiological variation instead of the treatment administrated (Nakano et al. 2014). Besides, the remaining haematological parameters (i.e. HB, RBC, MCHC, RDW, PLT, NEUT, MON, LYM, EOS, BAS, and WBC) showed no significant differences between the control and the treated groups. Thus, the results suggested that the oral intake of nypa sap presents no toxicity to the blood system.

TABLE 1. Effects of *N. fruticans* Wurmb. sap after treatment (14-days) on the haematological parameters of rats

Parameter	<i>N. fruticans</i> Wurmb. sap					
	Units	Control	5 mg/kg	50 mg/kg	300 mg/kg	2000 mg/kg
HB	g/L	142.00±12.08	145.60±8.08	153.80±13.55	147.60±11.01	149.20±5.81
RBC	x 10 ¹² /L	7.83±0.95	7.92±0.66	8.84±0.96	8.20±0.81	8.29±0.33
MCV*	fL	61.40±2.70	59.00±0.71	55.80±3.701*	57.20±2.77	57.40±1.67
MCH	pg	18.40±1.14	18.6±0.89	17.40±0.55	18.00±0.71	18.20±0.45
MCHC	g/L	296.60±11.06	312.60±15.01	313.20±13.08	315.60±7.16	313.36±8.67
RDW	%	15.00±2.14	14.34±1.03	16.20±2.00	14.24±1.51	14.64±1.50
Platelets	x 10 ⁹ /L	906.20±303.13	865.60±149.47	742.60±250.97	819.40±121.56	851.80±71.61
Total WBC	x 10 ⁹ /L	7.02±7.09	8.82±4.07	9.16±6.34	9.78±4.53	5.06±1.05
Neutrophils	x 10 ⁹ /L	1.36±1.48	1.54±0.82	2.14±1.43	2.14±1.82	2.06±0.33
Lymphocytes	x 10 ⁹ /L	4.70±4.68	6.54±3.32	5.72±4.25	6.56±2.41	3.62±0.66
Monocytes	x 10 ⁹ /L	0.58±0.70	0.44±0.29	0.46±0.32	0.50±0.16	0.44±0.13
Eosinophil	x 10 ⁹ /L	0.32±0.49	0.26±0.21	0.82±1.24	0.52±0.89	0.10±0.07
Basophils	x 10 ⁹ /L	0.00±0.00	0.00±0.00	0.00±0.00	0.00±0.00	0.00±0.00

Note: Values are expressed as means±SD where n=5

*Significant difference between control and treatment groups at p<0.05

BIOCHEMISTRY EXAMINATIONS

The findings of the biochemistry analysis are shown in Table 2. The most important task of the liver and kidney is to remove harmful substances from the body (Tripathy et al. 2016). Based on our results, the levels of ALT, AST, ALP, bilirubin, and creatinine in the treated groups showed no significant difference as compared to the control group. These indicated that a high dose of nypa sap does not contribute to toxicity on both kidney and liver organs. On the other hand, the high dose treatments of nypa sap (300 and 2000 mg/kg) lead to a significant decrease in blood glucose level in the studied rats. However, this decrease has no clinical significance as the value obtained in this study was within the normal range. It is noteworthy that our findings are consistent with previous reports that showed *N. fruticans* Wurmb. vinegar possesses anti-diabetic and anti-hyperglycaemic properties as a significant improvement in serum insulin levels was documented (Yusoff et al. 2015a, 2015b). The same research also addressed that the vinegar extract could delay carbohydrate absorption by inhibiting glucose transporters in the gastrointestinal tract that lead to the suppression of postprandial hyperglycaemia (Yusoff et al. 2015a).

Furthermore, the extract can also inhibit α -glucosidase and α -amylase activities which are involved in carbohydrate digestion.

Reza et al. (2011) reported that the methanolic extract of *N. fruticans* Wurmb. leaves and stem displays anti-glycaemic properties following experiments performed on glucose-loaded hyperglycaemic mice. Similarly, high doses of nypa palm vinegar could effectively reduce food intake and may potentially alleviate obesity based on a study conducted on high-fat-diet-induced obese mice (Beh et al. 2017). Another study also showed that the extract of *N. fruticans* Wurmb. seed mesocarp has the potential to lower blood glucose (Martin et al. 2017). These studies showed that *N. fruticans* Wurmb. (vinegar, stem, leaves, and seed mesocarp) strongly exhibits anti-diabetic and anti-hyperglycaemic properties by inhibiting the activity of α -amylase enzymes which in turn reduce monosaccharide intake in the body. Thus, nypa sap might have a similar compound that could also inhibit the absorption of glucose in the small intestine. To the best of our knowledge, this is the first study that shows the ability of nypa sap to lower blood glucose level as the previous studies only focused on vinegar, leaves, stem, and seed mesocarp from this plant.

TABLE 2. Effects of *N. fruticans* Wurmb. sap after treatment (14-days) on biochemistry parameters of rats

Parameter	Units	<i>N. fruticans</i> Wurmb. sap				
		Control	5 mg/kg	50 mg/kg	300 mg/kg	2000 mg/kg
Glucose *	mmol/L	7.58±2.25	7.50±1.82	6.22±1.29	5.24±0.41*	5.36±0.88*
Liver function test						
Total protein	g/L	75.60±4.83	76.40±4.45	77.20±2.77	78.60±5.73	72.40±5.64
Total bilirubin	µmol/L	0.00	0.00	0.00	0.00	0.00
Albumin	g/L	39.20±1.92	40.20±4.09	37.60±3.91	42.80±2.77	37.80±3.27
Globulin	g/L	36.40±4.93	36.20±2.95	39.60±3.58	35.80±3.35	34.60±3.36
A/G ratio		1.10±0.14	1.12±0.15	0.96±0.17	1.18±0.08	1.10±0.10
ALT (Alanine aminotransferase)	U/L	46.60±9.40	43.20±9.18	43.60±7.09	40.00±8.28	45.00±7.84
AST (Aspartate transaminase)	U/L	182.40±28.75	189.20±25.63	173.60±20.48	186.80±25.01	192.20±24.45
ALP (Alkaline phosphatase)	U/L	106.60±60.42	116.80±20.29	114.20±58.92	75.40±21.22	109.80±45.88
Kidney function test						
Urea	mmol/L	7.90±0.99	8.00±0.83	7.20±1.20	8.20±0.80	6.80±0.91
Creatinine	µmol/L	33.20±1.48	34.00±4.12	29.40±2.70	37.00±11.25	35.00±7.35
Uric acid	mmol/L	0.12±0.05	0.13±0.04	0.10±0.02	0.15±0.15	0.11±0.04
Electrolyte						
Sodium	mmol/L	143.20±2.17	143.00±0.71	142.80±2.68	141.80±0.84	141.00±1.22
Potassium	mmol/L	5.44±0.45	5.34±0.13	5.32±0.67	5.32±0.37	5.34±0.59
Chloride	mmol/L	99.60±0.89	99.60±1.95	100.00±1.87	101.40±2.07	102.40±1.14
Lipid profile						
Total cholesterol	mmol/L	2.06±0.22	2.24±0.43	2.18±0.29	2.06±0.42	1.82±0.50
Triglyceride	mmol/L	1.57±0.13	1.54±0.79	1.44±0.25	1.46±0.18	1.48±0.14
HDL	mmol/L	0.46±0.03	0.54±0.16	0.52±0.04	0.49±0.11	0.46±0.15
LDL	mmol/L	1.34±0.22	1.22±0.20	1.28±0.30	1.22±0.29	1.14±0.30

Note: Values are expressed as means±SD where n=5

*Significant difference between control and treatment groups at p<0.05

HISTOPATHOLOGY ANALYSIS

Histological assessment of kidneys from the rats also showed that no morphological changes or deleterious effects were found in the histological examination of kidneys from rats treated with 5, 50, 300, and 2000 mg/

kg dosage of nypa sap (Figure 2) when compared to control group. This experiment did not detect any evidence for glomerular alteration in the histology section of kidneys. However, mild lymphocytic infiltration within the interstitium (Figure 3) was observed in the kidney of

one rat from the low-dose group (5 mg/kg), which was considered to be incidental and not dose-related because it occurred only in one animal (Nakano et al. 2014). This observation might not be caused by the treatment as the levels of creatinine, urea, and uric acid in the blood were normal. Previous studies have showed that the non-toxic

properties of nypa palm sugar and nypa sap in a brine shrimp toxicity assay where the value of LC50 was at 184 mg/mL (Sabri et al. 2018) and 271.7 mg/mL, respectively (Hafizi et al. 2018). Therefore, the presence of *N. fruticans* Wurmb. sap in the rats may not cause toxicity to the kidney after acute exposure.

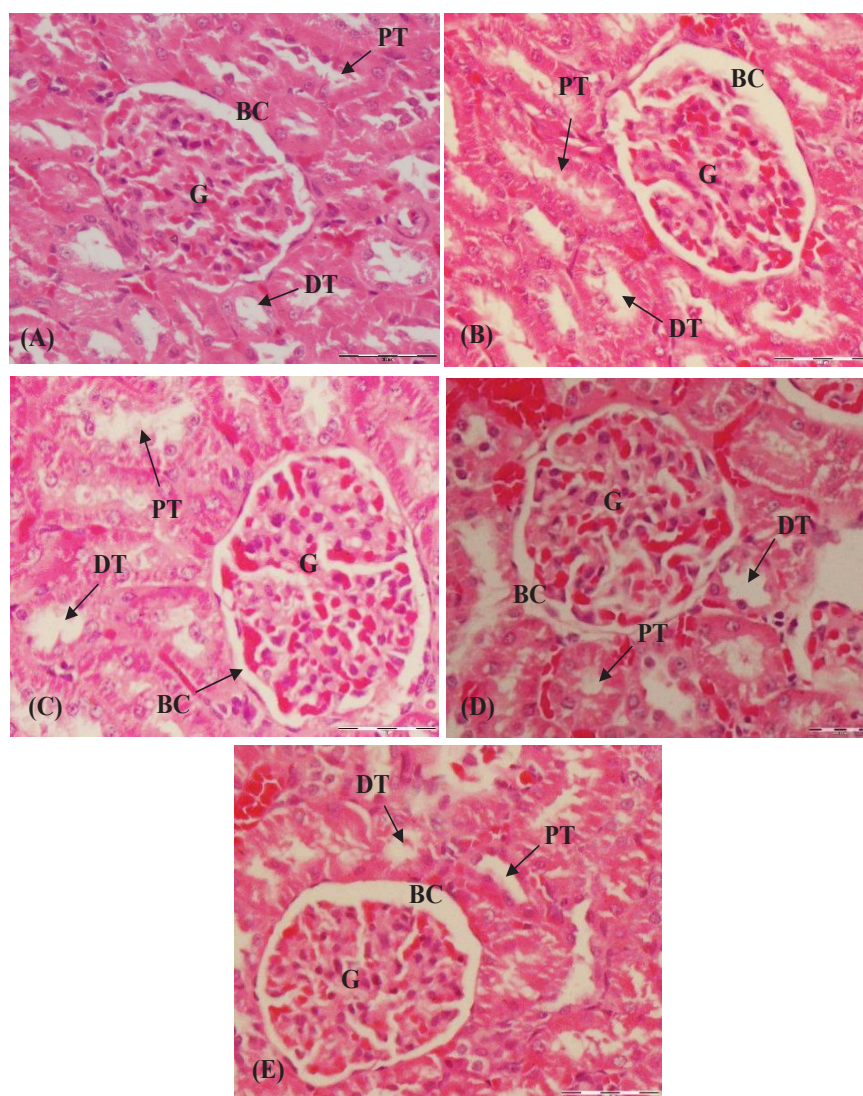


FIGURE 2. Selected kidney tissue sections of rats administered with normal saline and nypa sap for 14 days showing the normal structure of Bowman's capsule (BC), proximal convoluted tubule (PT), distal convoluted tubule (DT), glomerulus (G): (a) normal saline, (b) 5 mg/kg, (c) 50 mg/kg, (d) 300 mg/kg, and (e) 2000 mg/kg

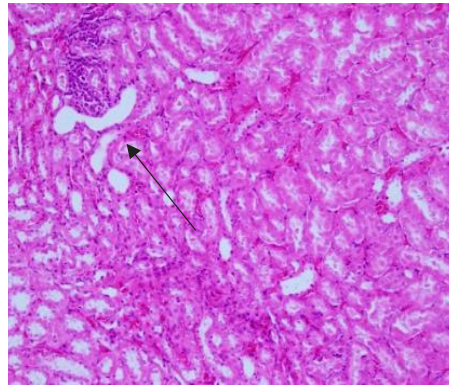


FIGURE 3. Kidney tissue section of a rat from the 5 mg/kg dose treatment group showing mild infiltration of lymphocytes within the interstitium

Histopathological analysis of liver tissues indicated that no significant changes were observed in rats treated with 5, 50, 300, or 2000 mg/kg doses of nypa sap, as well as in the control group, suggesting there were no toxic effects observed (Figure 4). No necrosis, cellular damage, hepatocyte necrosis, or steatosis appeared in the histology sections. However, mild portal inflammation consisting of lymphocytes, plasma cells, and eosinophils were detected in the histological analysis of one of the rat in the 5 mg/kg dose treatment group (Figure 5). As only one animal

showed the pathological changes, it was deduced that the nypa sap might not be capable of inducing hepatotoxicity (Nakano et al. 2014). A previous study reported that *N. fruticans* Wurmb. exhibits hepatoprotective activity as an aqueous extract of vinegar made from this plant restored the histological appearance of hepatocytes with stronger effect was observed in the higher doses (Yusoff et al. 2017). Based on the results of our study, nypa sap is considered to be safe for consumption as it did not cause any adverse effects on the liver.

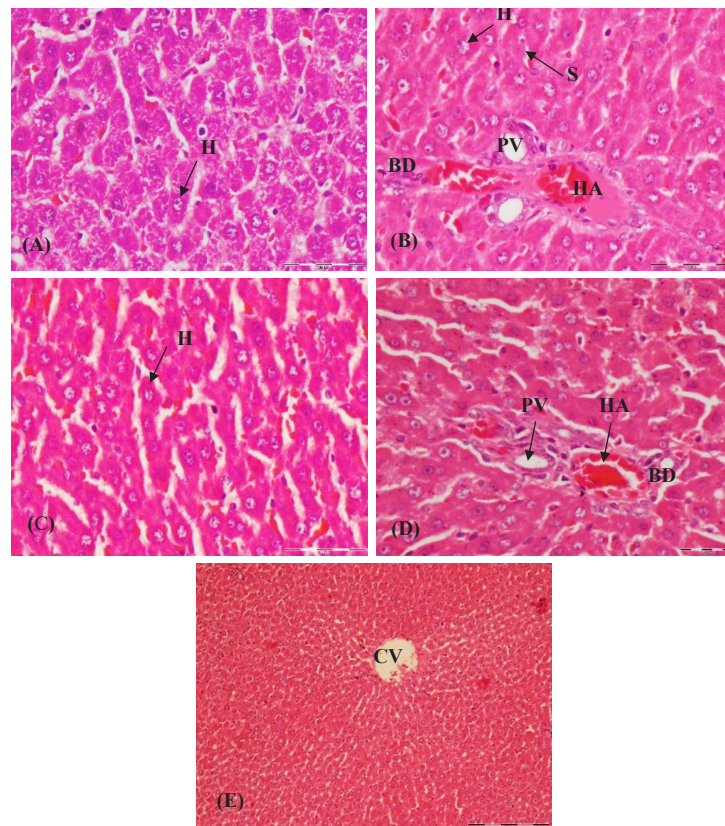


FIGURE 4. Selected liver tissue sections of rats administered with normal saline and nypa sap for 14 days showing normal structure of hepatocytes (H), sinusoids (S), central vein (CV), hepatic portal vein (PV), hepatic artery (HA), bile duct (BD): (a) normal saline, (b) 5 mg/kg, (c) 50 mg/kg, (d) 300 mg/kg, and (e) 2000 mg/kg

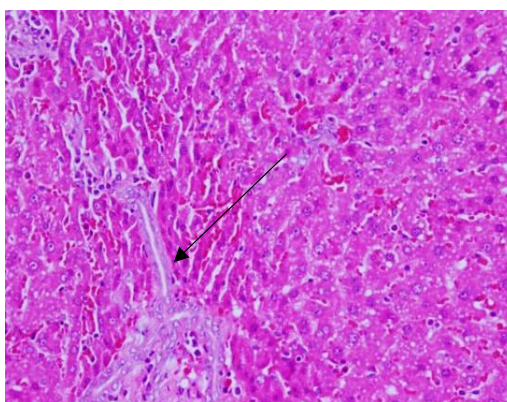


FIGURE 5. Liver tissue section of a rat from the 5 mg/kg dose treatment group showing mild portal inflammation

Additionally, nypa sap did not produce any symptoms of toxicity or mortality among the treated rats throughout the study period. Histopathological examination showed that no morphological changes or deleterious effects were found on histological features of the kidney and liver sections after oral administration of nypa sap. Moreover, histology sections also showed no necrosis or cellular damage. According to OECD guidelines, nypa sap is classified in the category 5 ($LD_{50} > 2000$ mg/kg body weight), meaning that the plant is considered practically non-toxic (OECD 2001a, 2001b). Therefore, it is proposed that the LD_{50} of *N. fruticans* Wurmb. sap is > 2000 mg/kg, categorised as safe and has no adverse effects on the rat models.

CONCLUSION

In summary, the present investigation suggested that *N. fruticans* Wurmb. sap is non-toxic since no significant changes were observed in haematological, biochemical, and histopathological assessments. On the other hand, a comprehensive experimental analysis of its chronic toxicity is needed for future development as a therapeutic alternative for the treatment of diseases.

ACKNOWLEDGEMENTS

The authors would like to acknowledge the funding support of this work by the Fundamental Research Grant Scheme (FRGS 152130454) from the Ministry of Higher Education, Malaysia. They also express gratitude to the research assistants and everyone who contributed to this study.

REFERENCES

- Aziz, A. & Jack, R. 2015. Total phenolic content and antioxidant activity in *Nypa fruticans* extracts. *Journal of Sustainability Science and Management* 10(1): 87-91.
- Bakoma, B., Berké, B., Eklu-Gadegbeku, K., Agbonon, A., Aklikokou, K., Gbeassor, M. & Moore, N. 2013. Acute and sub-chronic (28 days) oral toxicity evaluation of hydroethanolic extract of *Bridelia ferruginea* Benth root bark in male rodent animals. *Food and Chemical Toxicology* 52: 176-179.
- Bandaranayake, W.M. 1998. Traditional and medicinal uses of mangroves. *Mangroves and Salt Marshes* 2(3): 133-148.
- Beh, B.K., Mohamad, N.E., Yeap, S.K., Ky, H., Boo, S.Y., Chua, J.Y.H., Tan, S.W., Ho, W.Y., Sharifuddin, S.A., Long, K. & Alitheen, N.B. 2017. Anti-obesity and anti-inflammatory effects of synthetic acetic acid vinegar and Nipa vinegar on high-fat-diet-induced obese mice. *Scientific Reports* 7(1): 1-9.
- Da Silva, A.R., Reginato, F.Z., Guex, C.G., Figueredo, K.C., Araldi, I.C.D.C., de Freitas, R.B., Boligon, A.A., Athayde, M.L., de Andrade Mazzanti, C.M., Hübscher, G.H. & Bauermann, L.D.F. 2016. Acute and sub-chronic (28 days) oral toxicity evaluation of tincture *Baccharis trimera* (Less) Backer in male and female rodent animals. *Regulatory Toxicology and Pharmacology* 74: 170-177.
- Ebana, R.U.B., Etok, C.A. & Edet, U.O. 2015. Phytochemical screening and antimicrobial activity of *Nypa fruticans* harvested from Oporo river in the Niger Delta Region of Nigeria. *International Journal of Innovation and Applied Studies* 10(4): 1120-1124.
- Giknis, M.L.A. & Clifford, C.B. 2006. *Clinical Laboratory Parameters for CrI: CD (SD) Rats*. Charles River Laboratories. https://www.criver.com/sites/default/files/Technical%20Resources/Clinical%20Laboratory%20Parameters%20for%20CrI-CD_SD_%20Rats%20-%20March%202006.pdf.

- Hafizi, S.A., Razip, A.M., Aliana, W.S. & Tarmizi, W.Y. 2018. Crystallization and biological studies of *Nypa fruticans* Wurmb. sap. *Indonesian Journal of Pharmaceutical Science and Technology* 1(1): 37-42.
- Ho, C.W., Aida, W.W., Maskat, M.Y. & Osman, H. 2007. Changes in volatile compounds of palm sap (*Arenga pinnata*) during the heating process for production of palm sugar. *Food Chemistry* 102(4): 1156-1162.
- Hossain, M.F. & Islam, M.A. 2015. Utilization of mangrove forest plant: Nipa palm (*Nypa fruticans* Wurmb.). *American Journal of Agriculture and Forestry* 3(4): 156-160.
- Kojima, S., Haruta, J., Enomoto, A., Fujisawa, H., Harada, T. & Maita, K. 1999. Age-related haematological changes in normal F344 rats: During the neonatal period. *Experimental Animals* 48(3): 153-159.
- Lu, S.Y. & Wu, H.C. 2004. Initial diagnosis of anaemia from sore mouth and improved classification of anaemias by MCV and RDW in 30 patients. *Oral Surgery, Oral Medicine, Oral Pathology, Oral Radiology, and Endodontology* 98(6): 679-685.
- Martin, F., Boris, N.S., Kengne, S.R., Chia, T.E. & Guy, T.N. 2017. Antioxidant and postprandial glucose-lowering potential of the hydroethanolic extract of *Nypa fruticans* seed mesocarp. *Biology and Medicine Journal (Aligarh)* 9(407): 1-6.
- Minh, N.P. 2014. Various factors influencing to the nipa (*Nypa fruticans*) wine fermentation. *International Journal of Multidisciplinary Research and Development* 2(2): 78-84.
- Mohd, Z.M.S., Mohamed, R.O. & Mohd, W.S. 2011. Determination of hydrocyanic acid in Nipah fruit (*Nypa fruticans*). *Malaysian Journal of Analytical Sciences* 15(2): 258-264.
- Nakano, M., Takahashi, H., Koura, S., Chung, C., Tafazoli, S. & Roberts, A. 2014. Acute and subchronic toxicity studies of pyrroloquinoline quinone (PQQ) disodium salt (BioPQQ™) in rats. *Regulatory Toxicology and Pharmacology* 70(1): 107-121.
- Nur Aimi, R., Abu Bakar, F. & Dzulki-fly, M.H. 2013. Determination of volatile compounds in fresh and fermented Nipa sap (*Nypa fruticans*) using static headspace gas chromatography-mass spectrometry (GC-MS). *International Food Research Journal* 20(1): 369-376.
- Nguyen, D.V., Sethapokin, P., Rabemanolntsoa, H., Minami, E., Kawamoto, H. & Saka, S. 2016. Efficient production of acetic acid from Nipa (*Nypa fruticans*) sap by *Moorella thermoacetica* (f. *Clostridium thermoacetum*). *International Journal of Green Technology* 2: 1-12.
- OECD. 2001a. *Guideline for Testing of Chemicals: Acute Oral Toxicity-Fixed Dose Procedure Test No 420*. Organisation for Economic Co-operation and Development (OECD).
- OECD. 2001b. *Guideline for Testing of Chemicals: Acute Oral Toxicity-Acute Toxic Class Method Test No 423*. Organisation for Economic Co-operation and Development (OECD).
- Osabor, V.N., Egbung, G.E. & Okafor, P.C. 2008. Chemical profile of *Nypa fruticans* from cross river estuary, South Eastern Nigeria. *Pakistan Journal of Nutrition* 7(1): 146-150.
- Phetrit, R., Chaijan, M., Sorapukdee, S. & Panpipat, W. 2019. Characterization of nipa palm's (*Nypa fruticans* Wurmb.) sap and syrup as functional food ingredients. *Sugar Tech* 22(1): 191-201.
- Prasad, N., Yang, B., Kong, K.W., Khoo, H.E., Sun, J., Azlan, A., Ismail, A. & Romli, Z.B. 2013. Phytochemicals and antioxidant capacity from *Nypa fruticans* Wurmb. fruit. *Evidence-Based Complementary and Alternative Medicine* 2013: 154606.
- Rahmatullah, M., Sadeak, S.M.I., Bachar, S.C., Hossain, M.T., Abdullah-al-Mamun, M., Jahan, N., Chowdhury, M.H., Jahan, R., Nasrin, D., Rahman, M. & Rahman, S. 2010. Brine shrimp toxicity study of different Bangladeshi medicinal plants. *Advances in Natural and Applied Sciences* 4(2): 163-167.
- Ramsingh, D. 2010. The assessment of the chronic toxicity and carcinogenicity of pesticides. *Hayes' Handbook of Pesticide Toxicology*. Canada: Academic Press. pp. 463-482.
- Reza, H., Haq, W.M., Das, A.K., Rahman, S., Jahan, R. & Rahmatullah, M. 2011. Anti-hyperglycemic and antinociceptive activity of methanol leaf and stem extract of *Nypa fruticans* Wurmb. *Pakistan Journal of Pharmaceutical Sciences* 24(4): 485-488.
- Sabri, W.M., Asaruddin, M.R.A.R., Sukairi, A.H. & Yusop, S.A. 2018. Antioxidant and cytotoxicity studies of *Nypa fruticans* (Nypa Palm Sugar) extract. *Indonesian Journal of Pharmaceutical Science and Technology* 1(1): 65-69.
- Tamizhazhagan, V. & Pugazhendy, K. 2015. The toxicity effect of Monocrotophos 36% E. C on the Hematology, *Labeo rohita* (Hamilton, 1882). *International Journal of Current Pharmaceutical Research* 7(4): 92-95.
- Tripathy, R., Pradhan, M.R., Srivastava, V., Das, A., Jhajharia, S. & Mohapatra, T.M. 2016. Protective efficacy of *Tridax procumbens* and *Ficus religiosa* against isoniazid and rifampicin induced hepatocellular damage in rats: A preliminary comparative evaluation on biochemical parameters. *Asian Journal of Pharmaceutical and Clinical Research* 9(4): 362-364.
- Yusoff, N.A., Lim, V., Al-Hindi, B., Abdul Razak, K., Widyawati, T., Anggraini, D., Ahmad, M. & Asmawi, M. 2017. *Nypa fruticans* Wurmb. vinegar's aqueous extract stimulates insulin secretion and exerts hepatoprotective effect on stz-induced diabetic rats. *Nutrients* 9(9): 1-12.
- Yusoff, N.A., Ahmad, M., al Hindi, B., Widyawati, T., Yam, M., Mahmud, R., Razak, K. & Asmawi, M. 2015a. Aqueous extract of *Nypa fruticans* Wurmb. vinegar alleviates postprandial hyperglycemia in normoglycemic rats. *Nutrients* 7(8): 7012-7026.
- Yusoff, N.A., Yam, M.F., Beh, H.K., Razak, K.N.A., Widyawati, T., Mahmud, R., Ahmad, M. & Asmawi, M.Z. 2015b. Anti-diabetic and antioxidant activities of *Nypa fruticans* Wurmb. vinegar sample from Malaysia. *Asian Pacific Journal of Tropical Medicine* 8(8): 595-605.

Siti Fatimah Roqiah Yahaya*, Niza Samsuddin & Suhana Mamat
Department of Biomedical Sciences
Kulliyah of Allied Health Science
International Islamic University Malaysia
Bandar Indera Mahkota
25200 Kuantan, Pahang Darul Makmur
Malaysia

Rozita Hod
Department of Community Health
Faculty of Medicine
UKM Medical Center
Jln Yaakob Latif, Bandar Tun Razak
56000 Cheras, Kuala Lumpur, Federal Territory
Malaysia

Nor Zamzila Abdullah
Department of Pathology & Laboratory Medicine
Kulliyah of Medicine
International Islamic University Malaysia
Bandar Indera Mahkota
25200 Kuantan, Pahang Darul Makmur
Malaysia

Nor Zamzila Abdullah
Consultant Chemical Pathologist
International Islamic University Malaysia Medical Center
Bandar Indera Mahkota
25200 Kuantan, Pahang Darul Makmur
Malaysia

Nor Azlina A Rahman
Department of Physical Rehabilitation Sciences
Kulliyah of Allied Health Science
International Islamic University Malaysia
Bandar Indera Mahkota
25200 Kuantan, Pahang Darul Makmur
Malaysia

*Corresponding author; email: sitifatihmahroqiah@gmail.com

Received: 22 January 2020

Accepted: 21 August 2020